

Epilepsy Surgery: Pediatric aspects

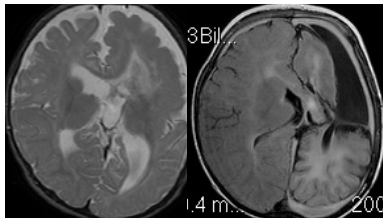
Bertil Rydenhag
Neurosurgery
Göteborg

Hemispherectomy

- Originally performed as a complete anatomical removal, insula was however most often spared.
- Due to late complications, it was considered important to have as much functioning subarachnoid space as possible intact for normal liquor circulation.
- This was the impetus to develop functional methods.

Functional Hemispherectomy

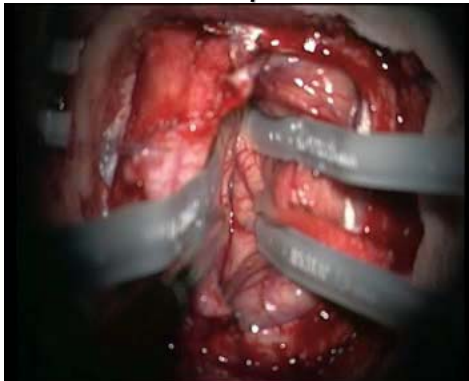
- The first type of functional hemispherectomy includes a relatively large central resection, hereafter a corpus callosotomy is made from inside the ventricular system, the remaining connections to the frontal lobe and occipital lobe are cut and the temporal lobe is resected



Further technical development

- Other groups, eg the Bonn-group presented techniques with less and less parenchymal resection, developing the procedure more into a disconnection
- Olivier Delalande introduced the hemispherotomy, where a minimal parietal resection is made, followed by a transection including undercutting of the insula.

Corpus Callosotomy

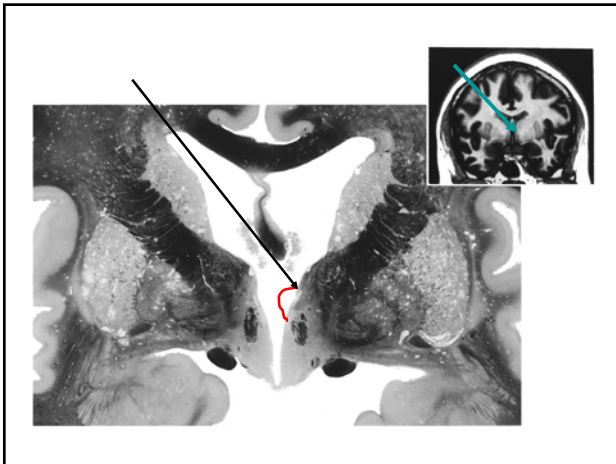


Corpus Callosotomy

- To stop interhemispheric spread of seizures, and stop synchronisation.
- The main indication is to prevent atonic seizures with multiple traumatisations
- Most commonly is a frontal disconnection done, but in some cases a complete disconnection in the first step.

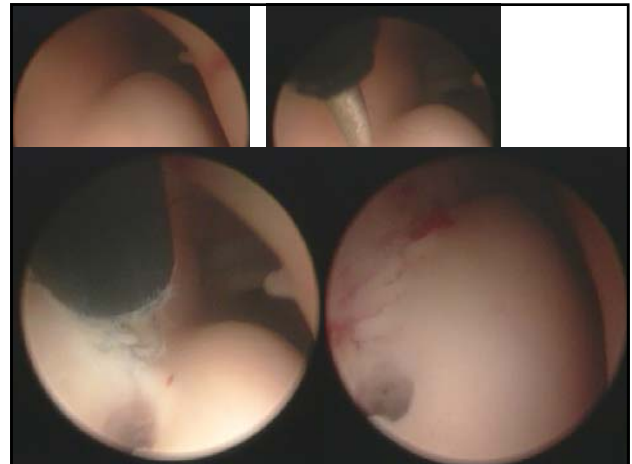
Corpus Callosotomy

- A complete disconnection may be done in two steps, with two separate craniotomies.
- It is however possible to do a safe complete disconnection via a single opening close to the coronar suture.
- Earlier complications were common, but with the microneurosurgical technique, complications should be very rare.
- The procedure has more and more been replaced by VNS.



Hypothalamic hamartoma

- Difficult group
- The surgical treatment menu:
 - Resection via pterion or transcallosally
 - Disconnection endoscopically intraventricularly, or via a pterional route.
 - Also radiofrequency heating has been used.
- Non-surgically stereotactic irradiation is used, eg the Gamma-knife



Tuberous Sclerosis

- Surgically a tuber can be removed, but the problem is to decide which one of the often multiple tubers is the epileptogenic one. Several tubers can be removed at different occasions, with good palliative effect.
- The surgical decision is based on the judgement of seizure start, also being aware of that another tuber may take over the generator role.

